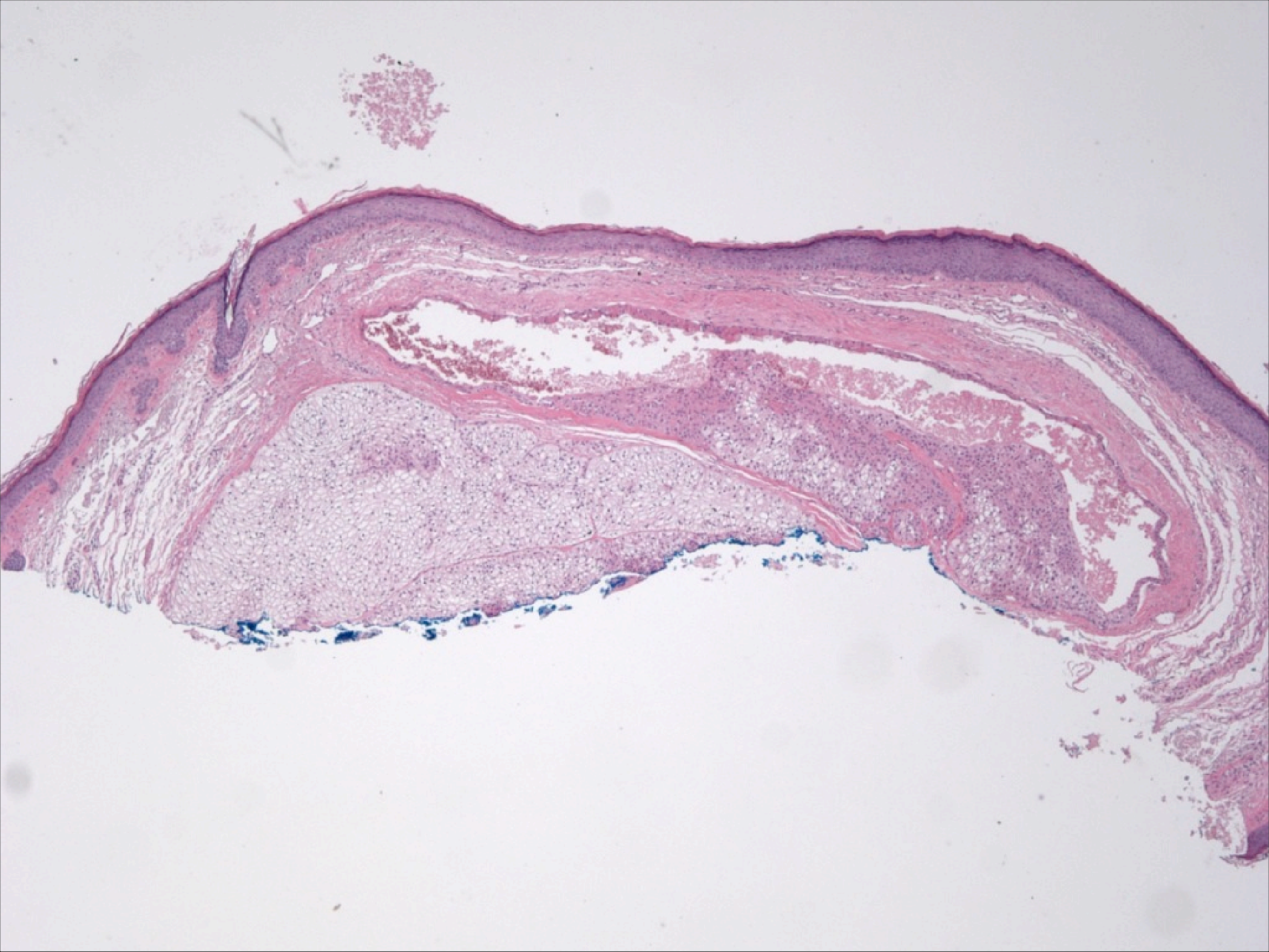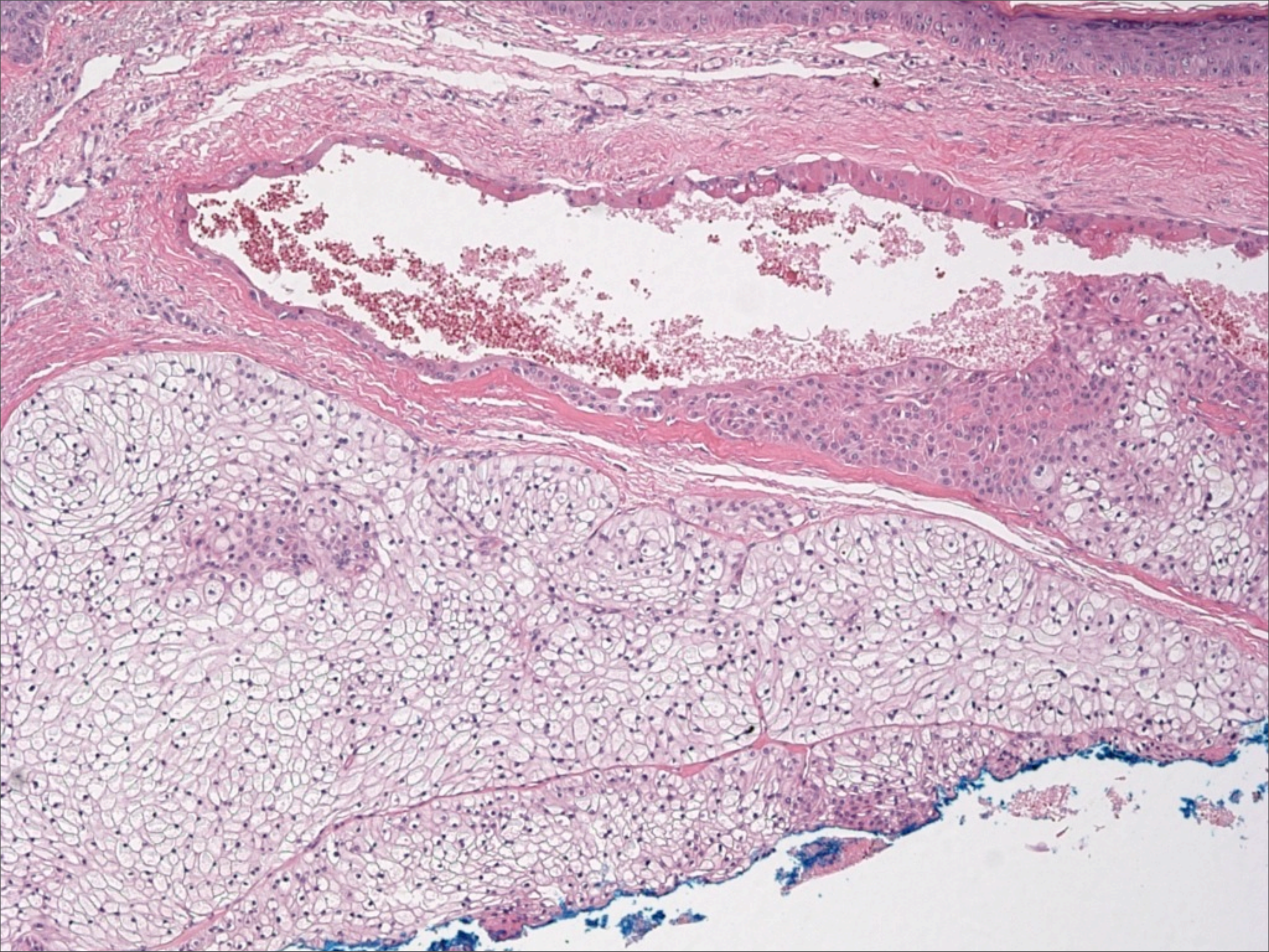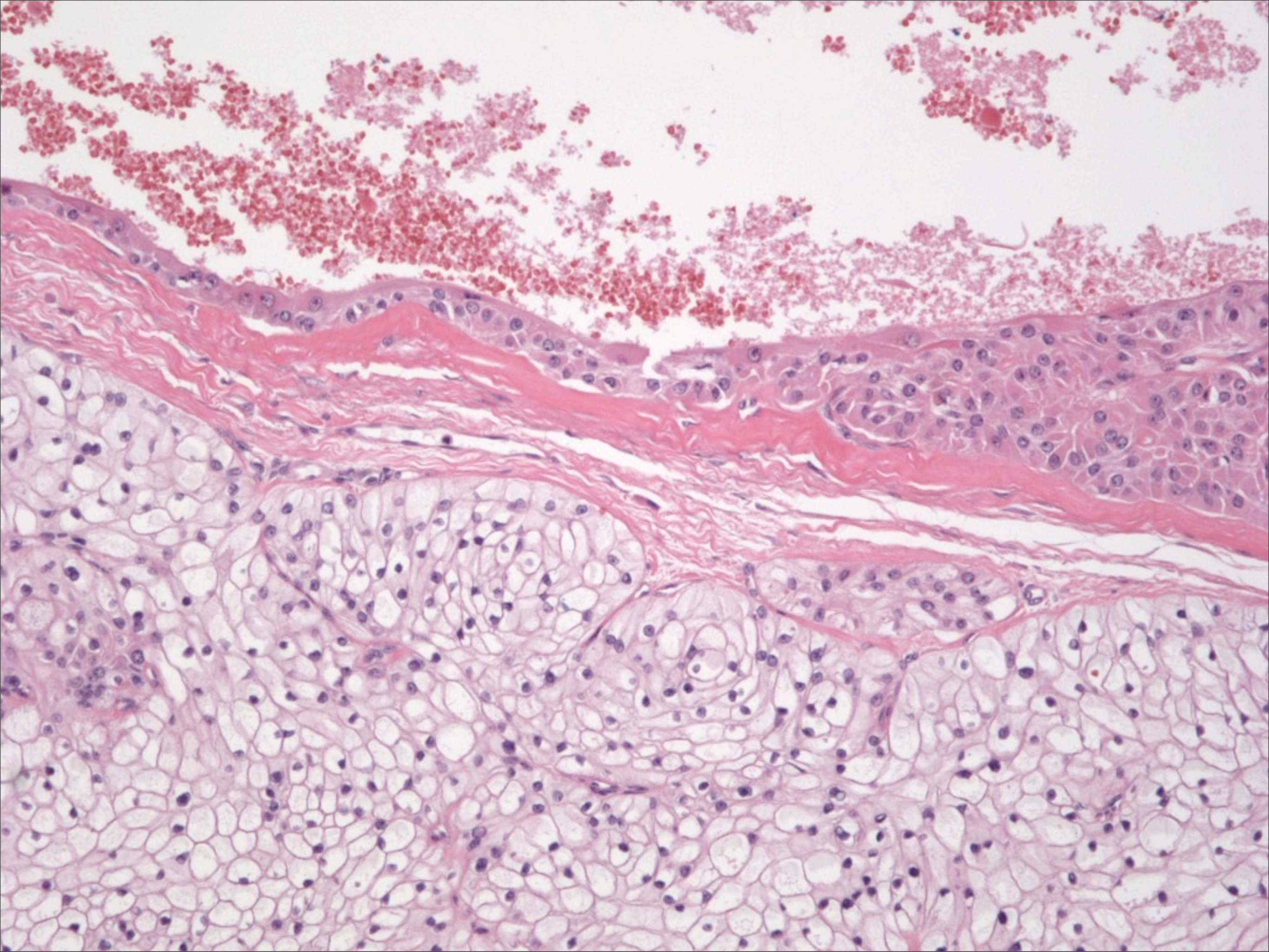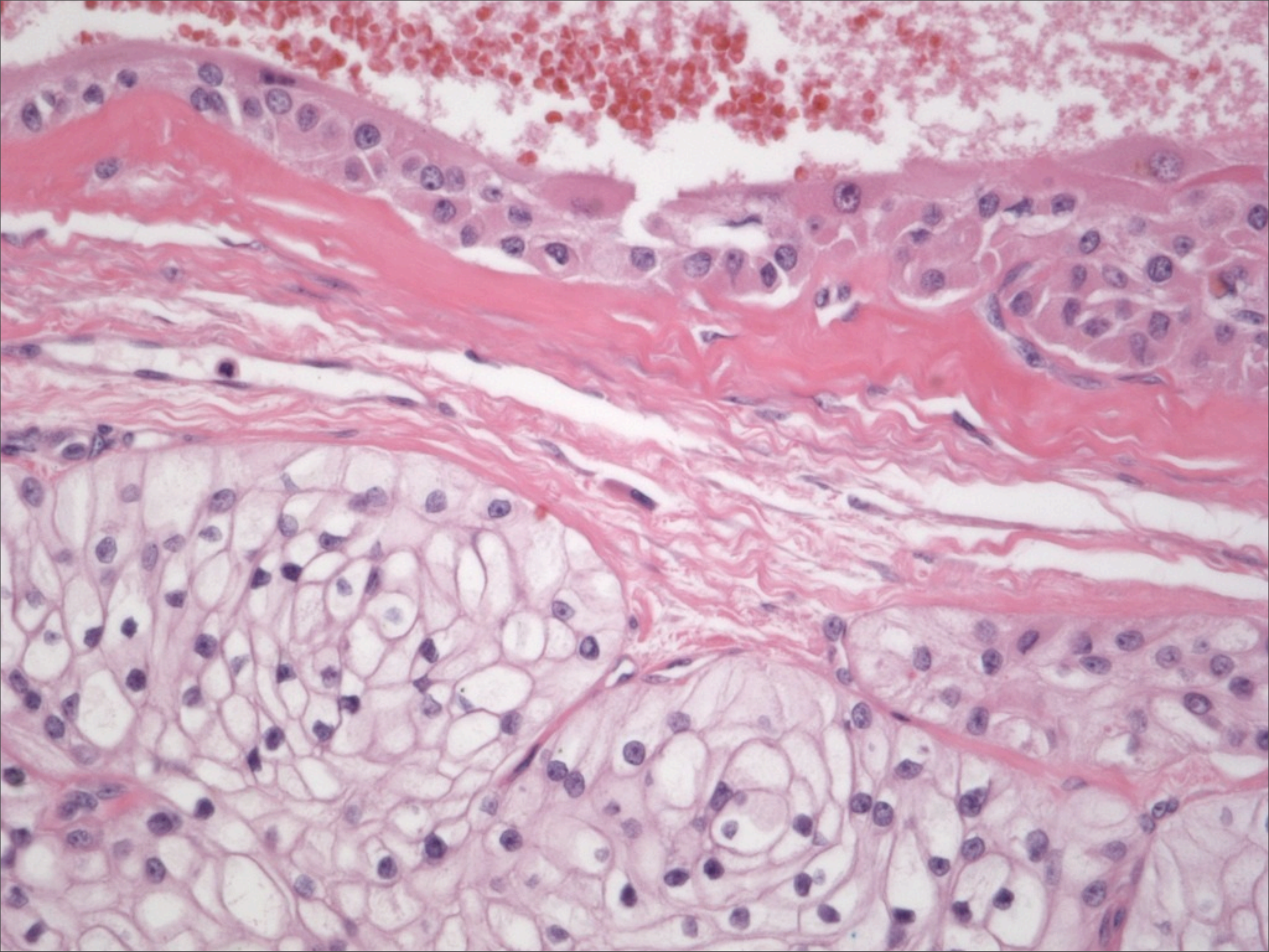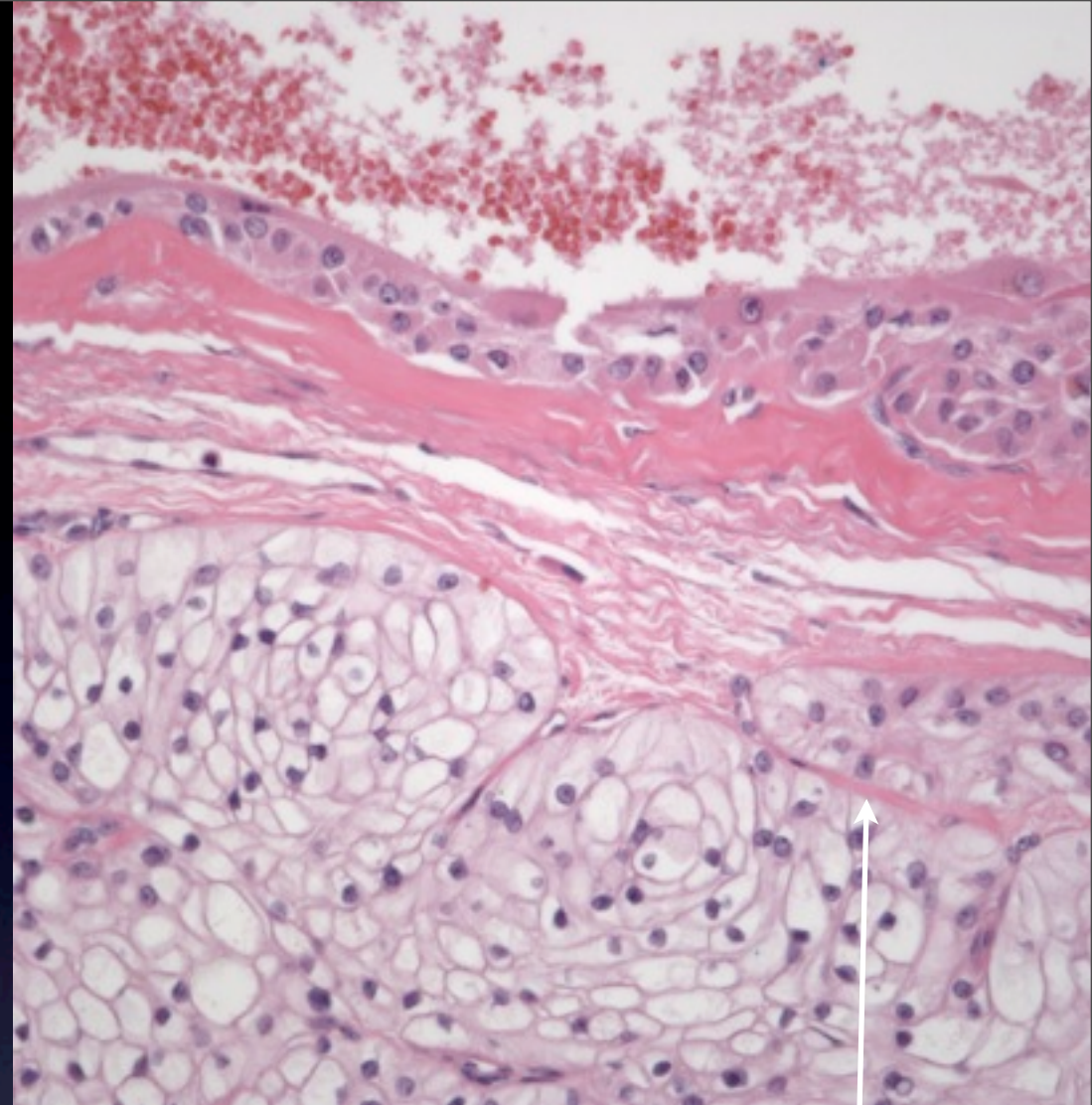
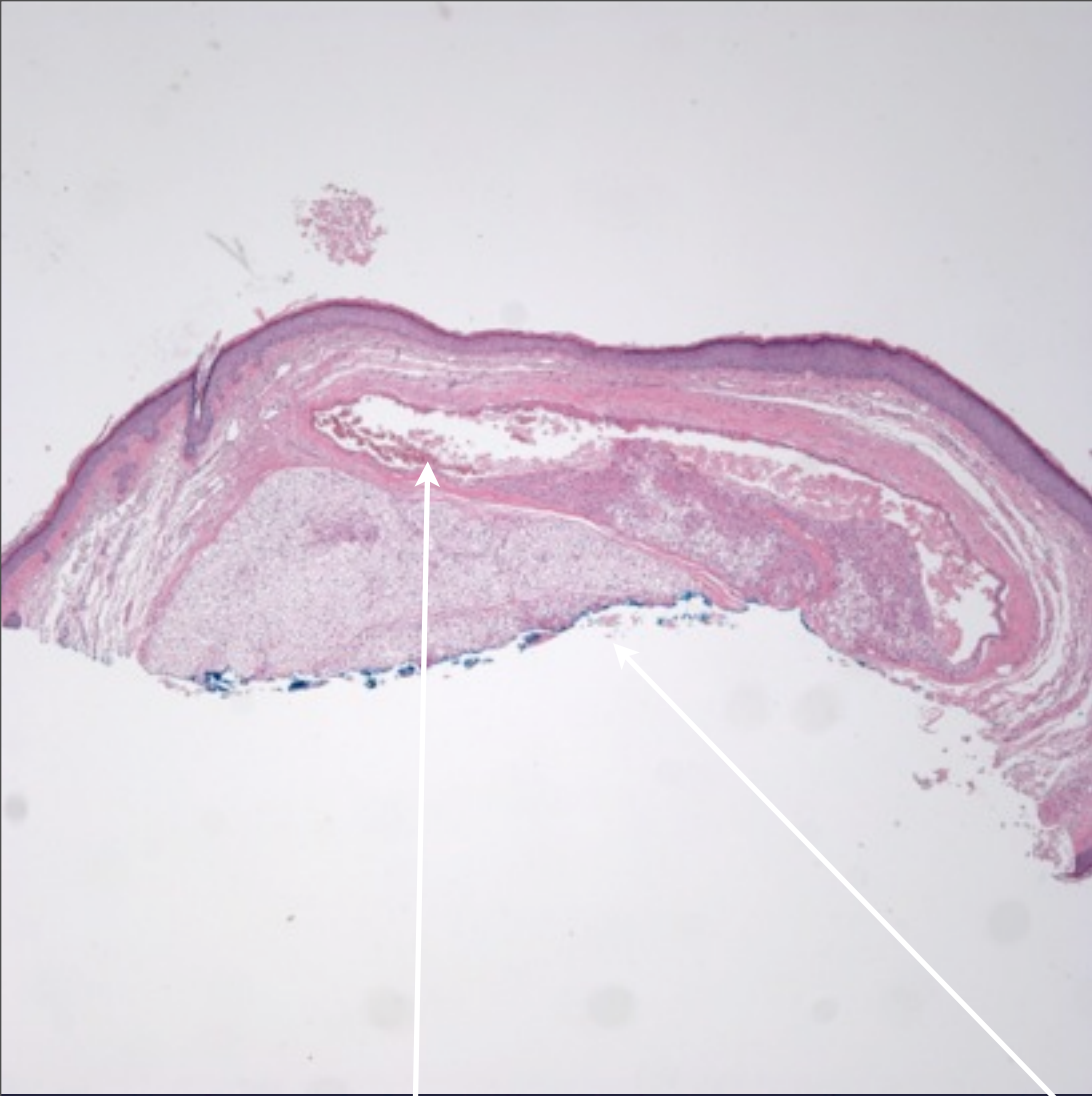


Clear Cell Hidradenoma



Dermal based nodules of cytologically bland clear cells

Basement membrane hyalinization

May show apocrine differentiation